

## Repair case performed by Dr. Feriduni – SHA-Lift, scar correction and FUE in 2 procedures

SHA-Lift, scar correction and FUE performed on a 32-year old Caucasian female with

- 2 FUT's ex domo
- Donor density of 84 FU/cm<sup>2</sup> occipital, 84 FU/cm<sup>2</sup> parietal, 76 FU/cm<sup>2</sup> temporal
- Hair diameter of ~ 52-62 microns

### Treatment plan

1. SHA-Lift to lower the hairline and extraction of wrong-placed and wrong-directed FU from FUT's ex domo.
2. Follicular Unit Extraction to attain an aesthetic reconstruction of the hairline and scar correction of FUT's ex domo.

### Performed procedures

1. SHA-Lift + extraction wrong-directed and wrong-placed FU (February 25, 2019)
2. Scar correction with Trichophytic closure + FUE with 1581 FU (August 14, 2019)  
Follicular Unit Extraction with 1581 FU:
  - \* 639 single hair FU
  - \* 613 double
  - \* 329 triple and quadruple hair FU

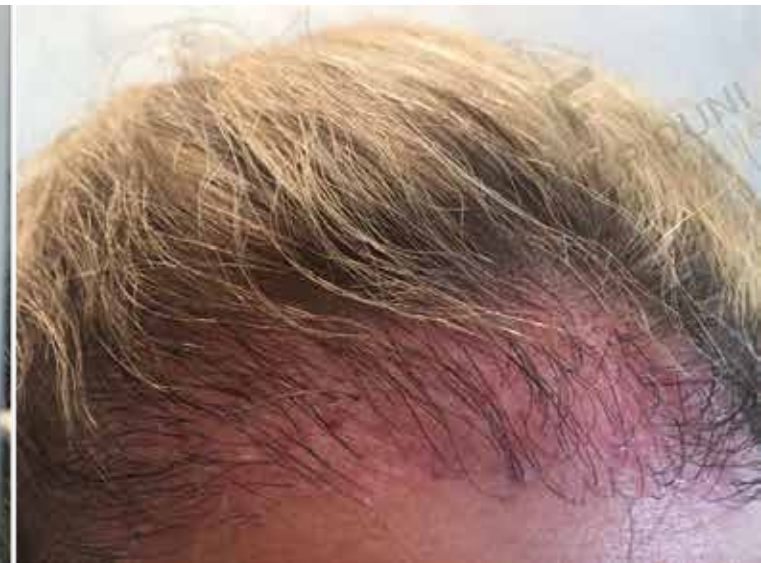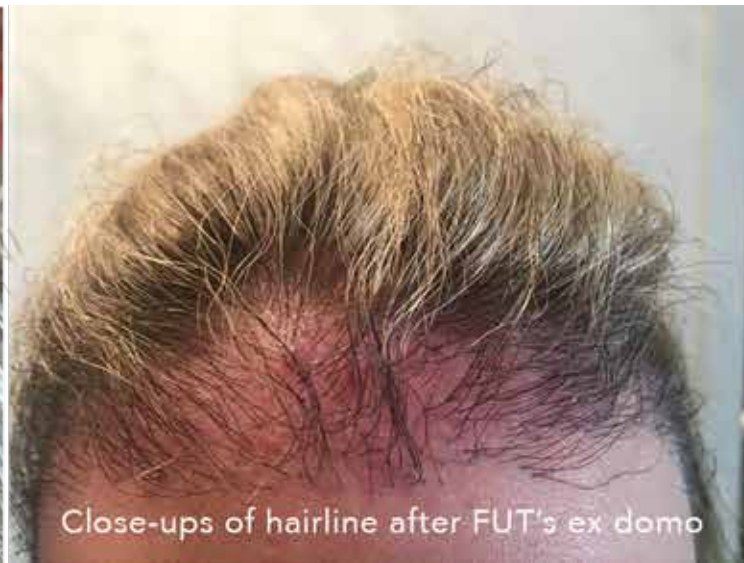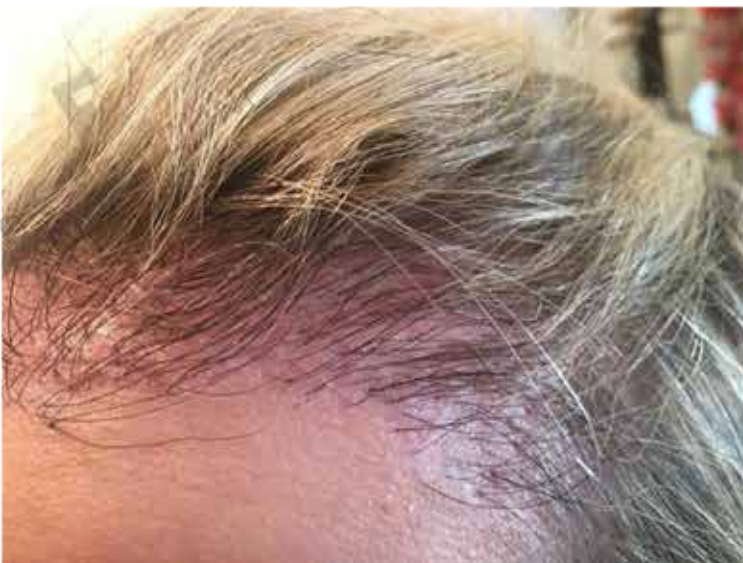HGI: 1,9

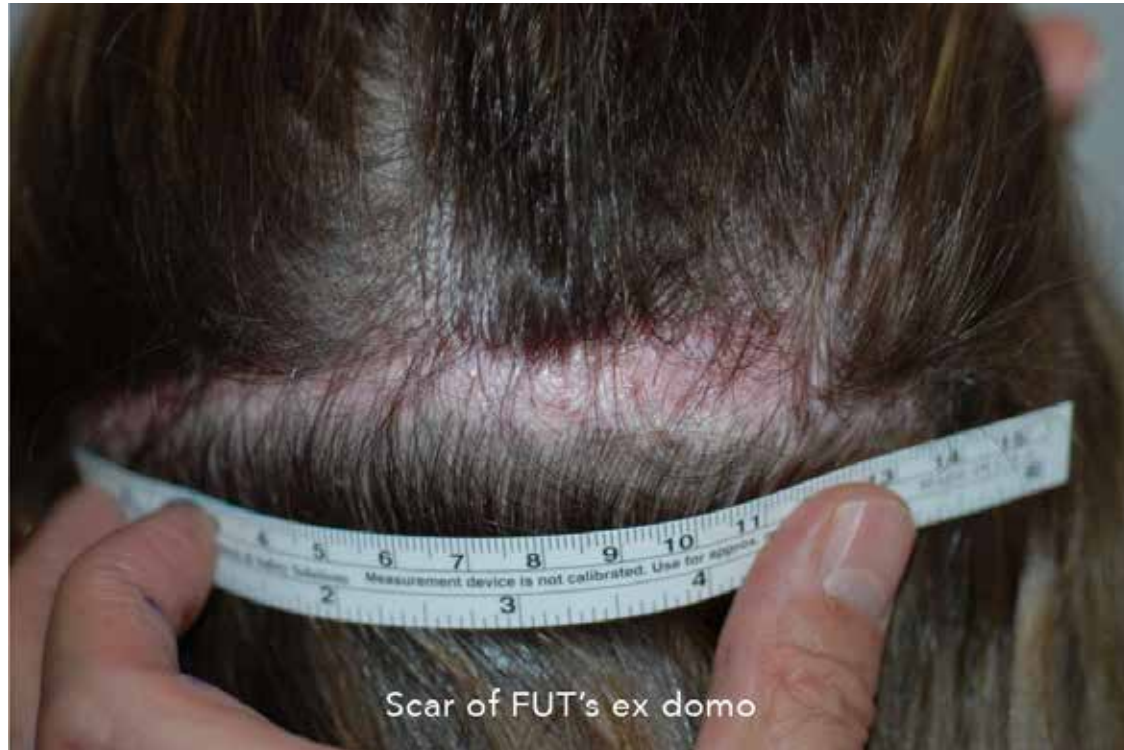Parallel incisions in custom-sized blades technique.  
Extraction performed by WAW-system with a 0.85 mm serrated trumpet punch.

No microscopic preparation of the follicular unit grafts.

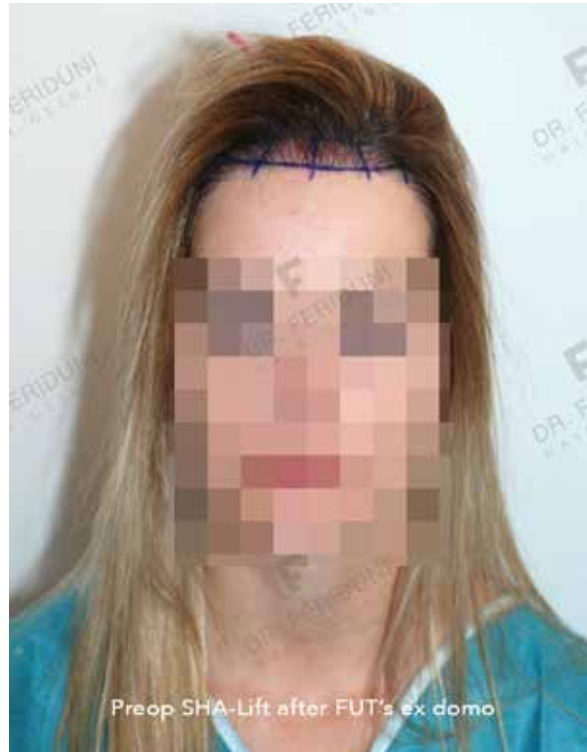Dr. Bijan Feriduni

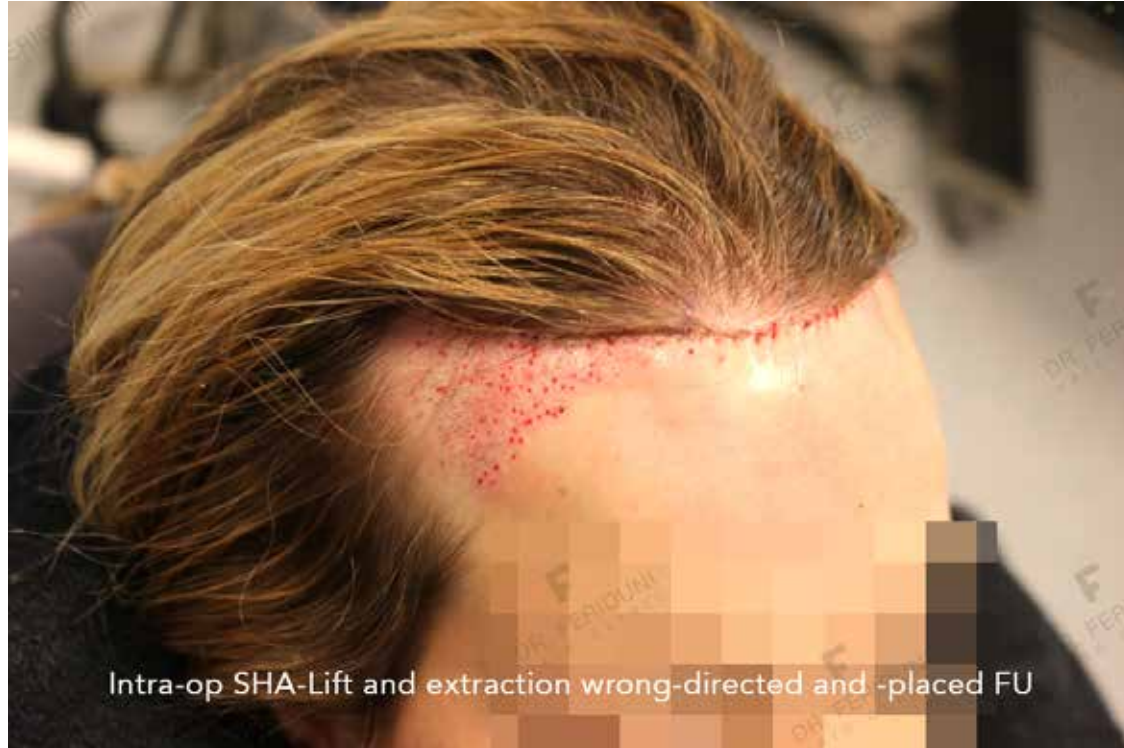Repair case:  
Poor results of FUT ex domo - hairline and scar



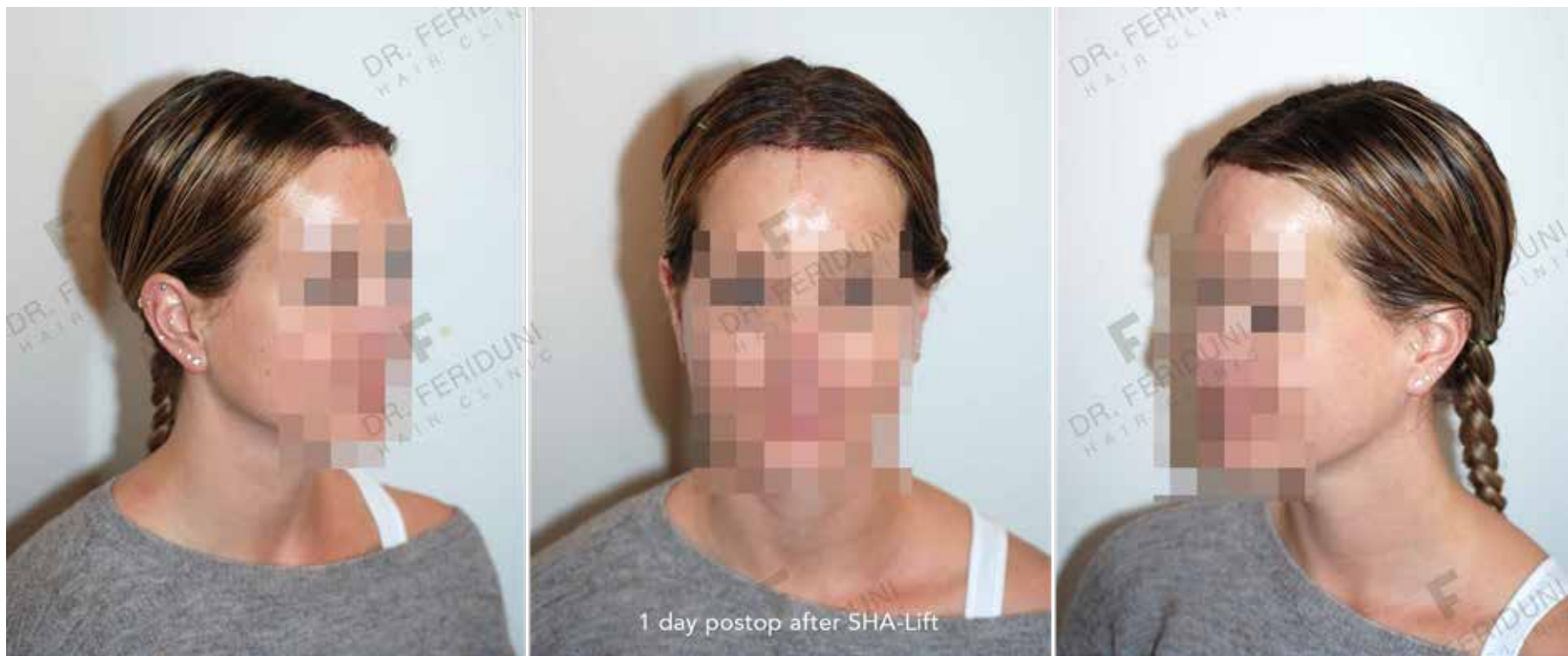

1. SHA-Lift and extraction wrong directed and -placed FU



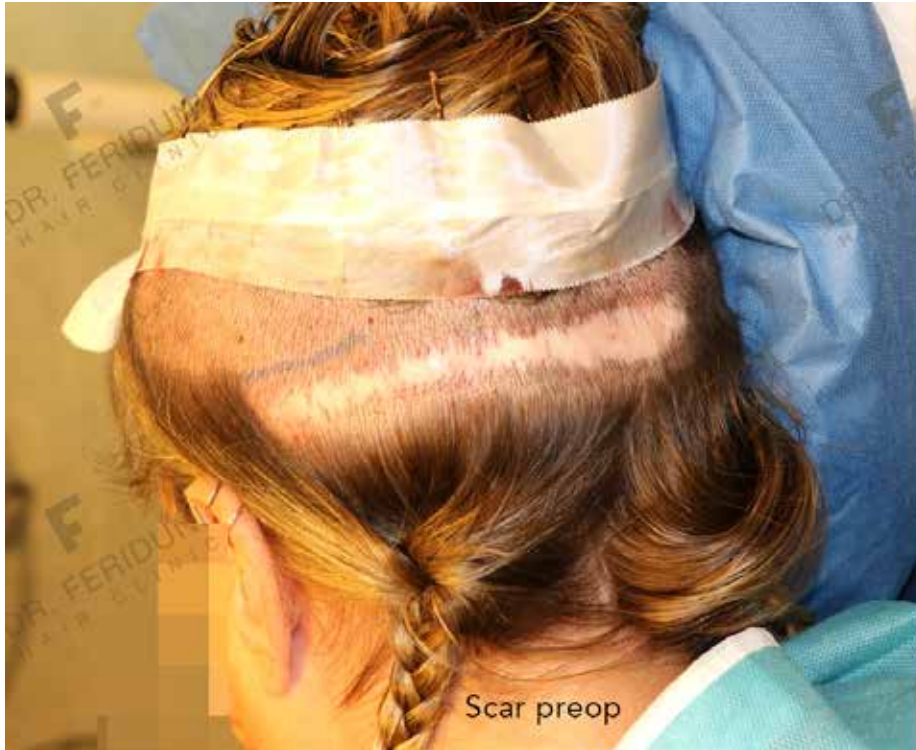

Intra-op SHA-Lift and extraction wrong-directed and -placed FU

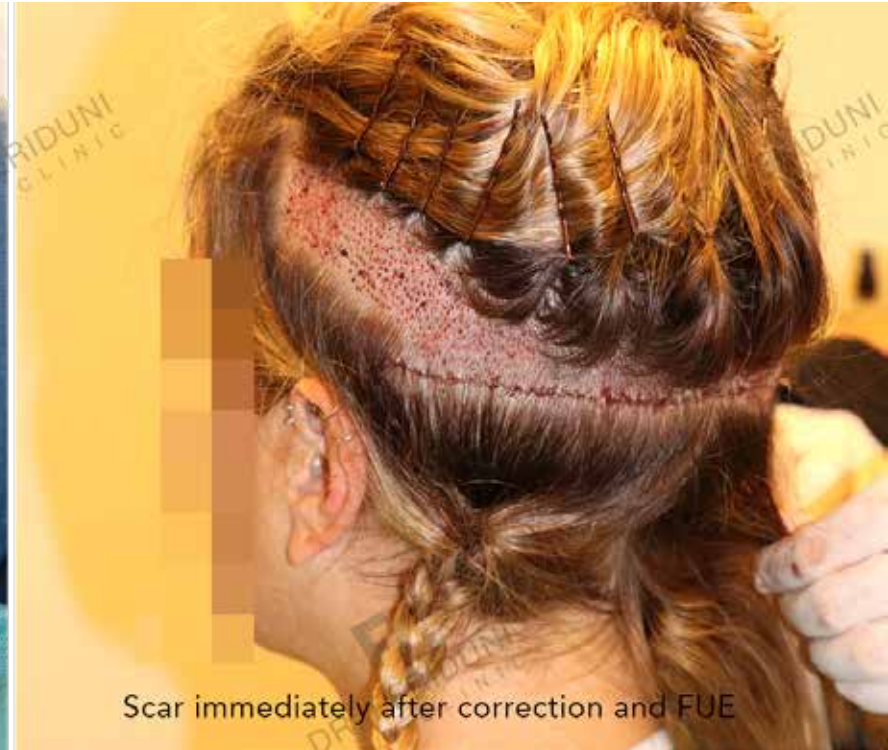



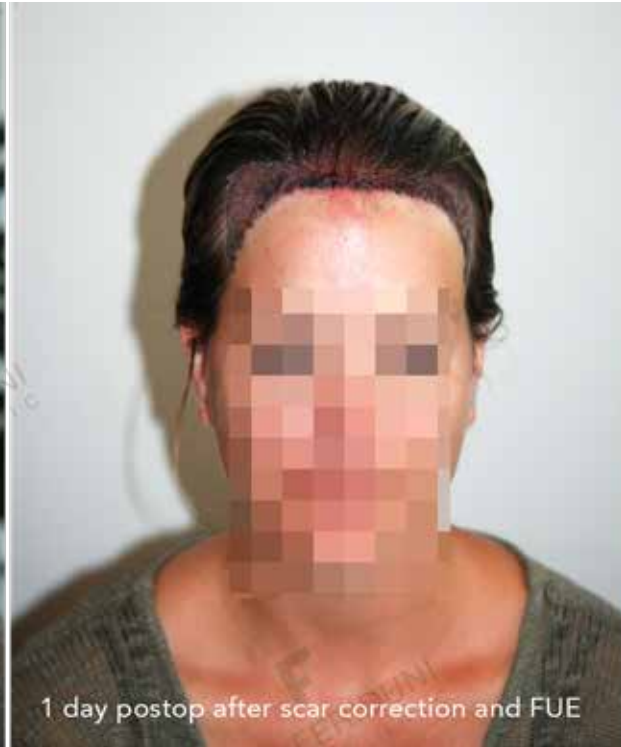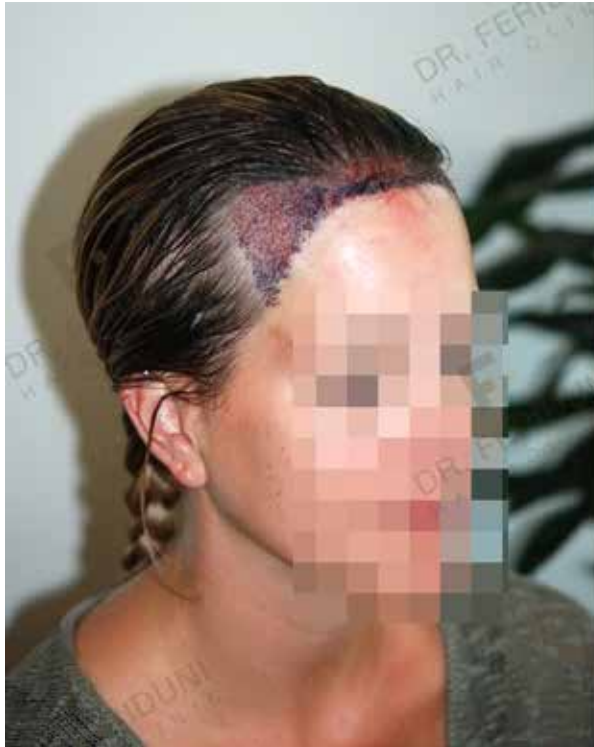2. Scar correction and FUE



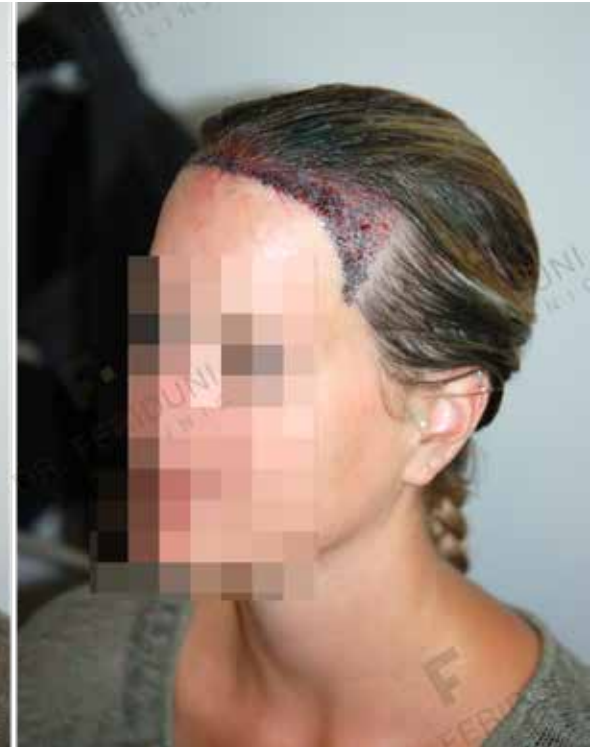Scar preop



Scar immediately after correction and FUE



1 day postop after scar correction and FUE



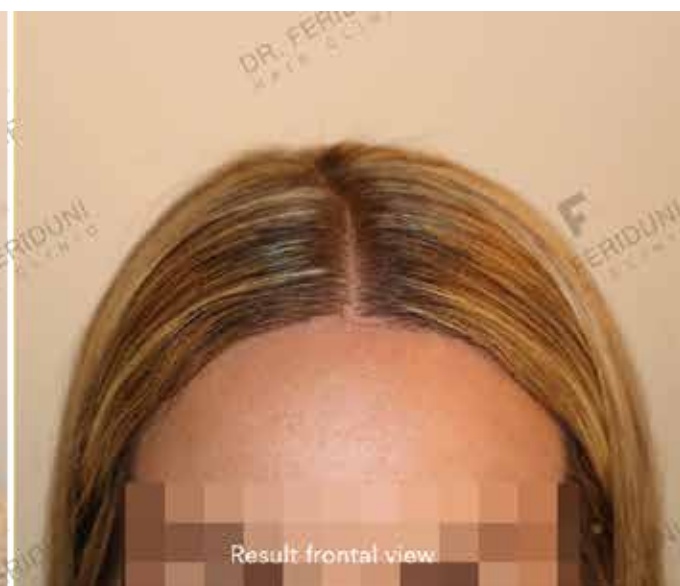


The result 10 months postop

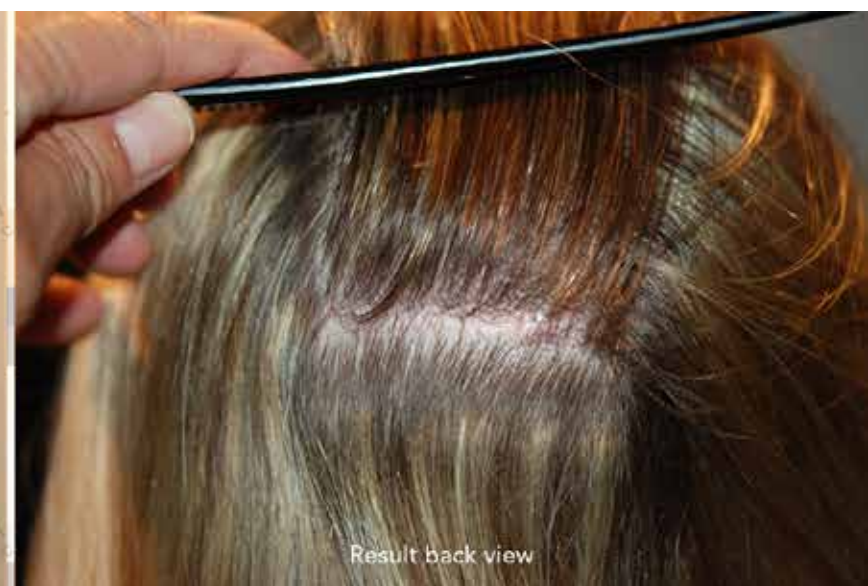



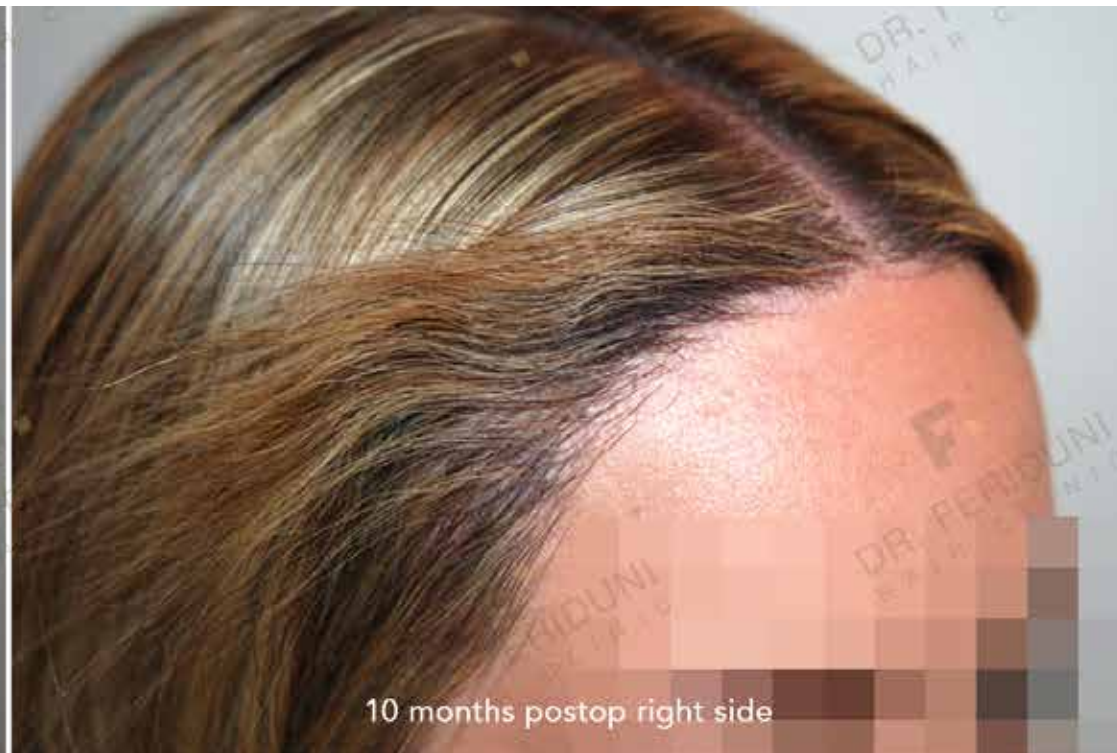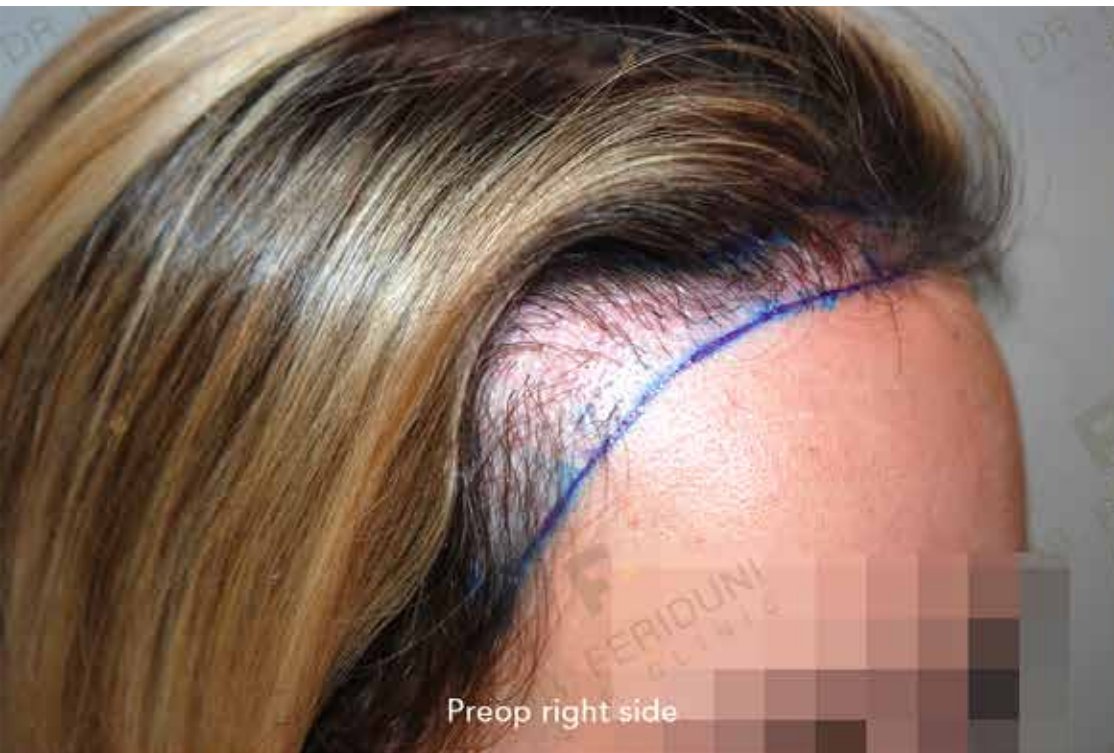Result top view



Result frontal view

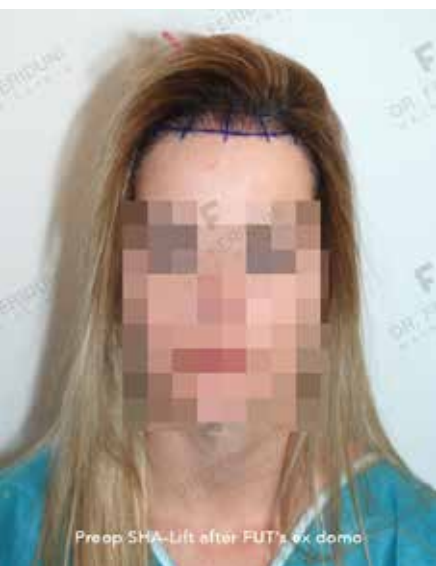

Result back view

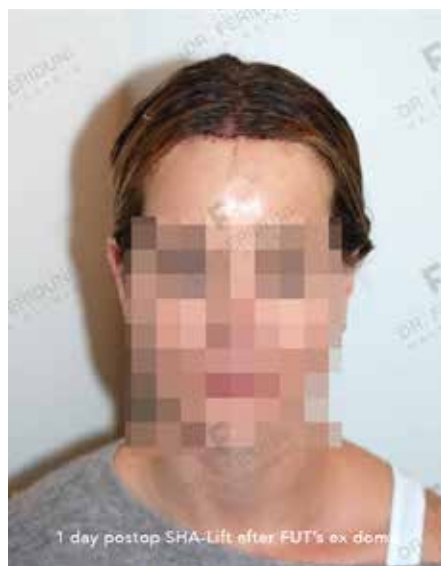



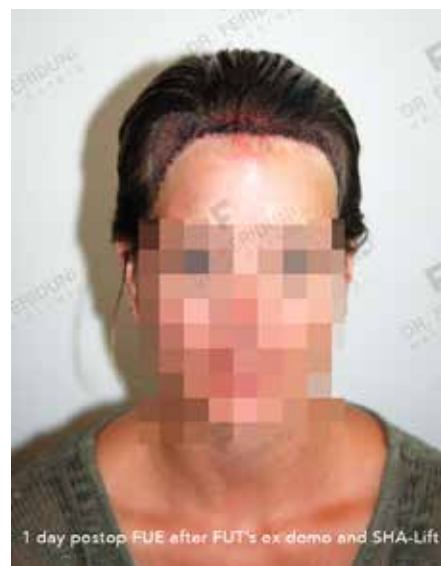Repair case by Dr. Feriduni: an overview



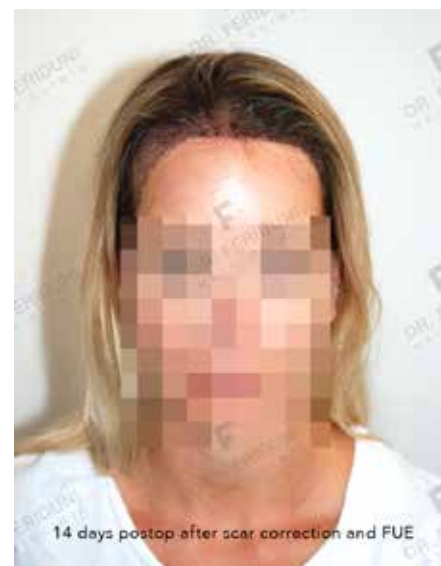Preop SHA-Lift after FUT's ex demo



1 day postop SHA-Lift after FUT's ex demo



1 day postop FUE after FUT's ex demo and SHA-Lift



14 days postop after scar correction and FUE



10 months postop after scar correction and FUE